



Scientific Electronic Archives

Issue ID: Vol.19 (4), Jul/Aug 2026, p. 1-9

DOI: <http://dx.doi.org/10.36560/19420262216>

+ Corresponding author: eduardopaula@pucgoias.edu.br

Anatomopathological aspects of histomoniasis in an Indian Peacock (*Pavo cristatus*) associated with aspergillosis

Felyphe Feliciano Silva ¹, Bruna Antunes Maschi ¹, Renata de Miranda Fernandes ¹, Tatiane Furtado de Carvalho ¹, Alessandra Aparecida de Medeiros Ronchi ¹, Alice Assunção dos Santos ², Ana Maria de Souza Almeida ³, Eduardo de Paula Nascente ² +

¹ Universidade Federal de Uberlândia

² Pontifícia Universidade Católica de Goiás

³ Universidade Federal de Goiás

Abstract. This study describes a case of histomoniasis in an Indian peafowl (*Pavo cristatus*) associated with coinfection by *Aspergillus* spp. The bird, raised in an environment shared with other gallinaceous species, presented clinical signs of apathy, hyporexia, and progressive weight loss, eventually progressing to death. The anatomopathological examination revealed necrotizing granulomatous hepatitis, fibrinonecrotic typhlitis, and necrotizing heterophilic pneumonia, with the presence of septate hyphae compatible with *Aspergillus* spp. and trophozoites of *Histomonas meleagridis* in the cecum. The findings indicate a fungal coinfection, potentiated by predisposing factors such as immunosuppression and unfavorable environmental conditions. This case report highlights the importance of differential diagnosis in ornamental birds and reinforces the need for appropriate sanitary management to prevent complex infectious diseases in exotic species.

Keywords: Ornamental birds; Parasitosis; Typhlitis.

Introduction

The species *Pavo cristatus*, also known as the Indian peacock, belongs to the family Phasianidae and is native to India, Sri Lanka, and Myanmar, inhabiting open tropical forests, savannas, and agricultural areas near human settlements (Delacour, 1977; Johnsgard, 1999). Its domestication history dates back approximately 3,000 years, having been bred in India and Persia as a symbol of beauty, royalty, and immortality (Ali & Ripley, 1981). With the expansion of empires such as the Greek and Roman, the peacock was introduced to Europe, establishing itself as a luxury ornamental bird among nobles and aristocrats—a tradition that persists to this day (Kear, 2005).

Biologically, the species exhibits pronounced sexual dimorphism; adult males measure from 1.8 to 2.3 m in length, including the long tail ornamented by ocellated feathers that can exceed 1.5 m, while females are smaller, measuring approximately 90 cm, with brownish-green plumage and lacking the exuberant tail. The average weight

of males ranges between 4 and 6 kg, and that of females between 2.5 and 4 kg (Delacour, 1977).

Peacocks are diurnal and terrestrial birds, generally gregarious outside the breeding season. They have an omnivorous diet consisting of seeds, insects, small reptiles, and fruits, playing a significant ecological role in insect control and seed dispersal (Ali & Ripley, 1981). At night, they seek refuge in tall trees as a form of protection against predators. In Brazil, the peacock is bred almost exclusively as an ornamental bird, commonly found in public gardens, rural properties, and leisure areas. Brazilian environmental legislation requires registration and authorization from IBAMA for the breeding and commercialization of these exotic birds to prevent improper introduction into the environment (IBAMA, 2013).

This species is susceptible to various infectious, parasitic, and nutritional diseases similar to those affecting other domestic galliforms. The multi-species rearing of ornamental birds, such as *Pavo cristatus* (Indian peacock), and domestic

poultry increases the risk of infectious disease transmission. For instance, it has been demonstrated that *Mycoplasma gallisepticum* was isolated from both peacocks and chickens kept in the same location, presenting similar clinical signs, including sinusitis, ocular discharge, and respiratory impairment, suggesting that chickens may act as reservoirs or vectors in mixed systems (Cookson & Shivaprasad, 1994). Similarly, it has been documented that young peacocks are highly susceptible to histomoniasis when housed with chickens and turkeys, reaching 100% morbidity and 84% mortality in experiments conducted by Lund & Chute (1972).

Histomoniasis is a parasitic disease caused by the protozoan *Histomonas meleagridis*, responsible for inducing necrotic lesions in the liver and cecum; it is also known as "blackhead disease" and is frequently fatal in susceptible birds. Under immunosuppressive conditions, the infection predisposes birds to secondary bacterial infections and other opportunistic pathogens due to the disruption of the mucosal barrier, which causes significant health impairment to the hosts, frequently resulting in high mortality rates (McDougald, 2005).

Therefore, the objective of the present study is to report a case of histomoniasis in an Indian peacock (*Pavo cristatus*) associated with *Aspergillus* spp. coinfection, highlighting the anatomopathological aspects and possible interactions between the involved agents, with an emphasis on predisposing factors and implications for the ornamental breeding of the species.

Material and Methods

An eight-month-old female Indian peacock (*Pavo cristatus*) carcass was submitted to the Animal Pathology Service of the Veterinary Hospital of the Federal University of Uberlândia (HOVET/UFU). According to the owner's report, the animal was raised in a small farm environment (*chácara*) under a mixed-species rearing system alongside nine other peacocks, as well as domestic chickens (*Gallus gallusdomesticus*) and guinea fowl (*Numida meleagris*).

The clinical history revealed that five peacocks in the flock exhibited signs consistent with systemic illness, including apathy, hyporexia, social isolation, progressive weight loss, and ruffled feathers. Given this scenario, antiparasitic treatment was instituted for all individuals using levamisole hydrochloride (Ripercol® 5%, 0.5 mL/animal, orally). Subsequently, birds showing more evident clinical signs were isolated in individual cages and administered intramuscular dexamethasone, following veterinary guidance (dosage not specified). Five days after the start of the therapeutic protocol, one of the females died, and the carcass was submitted for anatomopathological examination. The necropsy was performed according to standardized protocols for avian species, including a detailed

external examination and systematic evaluation of internal organs. During the procedure, representative fragments of the lungs, liver, and ceca were collected and fixed in a 10% neutral buffered formalin solution.

Following fixation, the tissues were routinely processed for histopathological examination, embedded in paraffin, sectioned at 4µm, and stained with Hematoxylin and Eosin (H&E). Special histochemical stains were employed, including Grocott–Gomori methenamine silver (GMS) to highlight fungal structures and Periodic Acid-Schiff (PAS) to enhance the visualization of protozoa. The slides were analyzed via light microscopy, and morphological findings were described based on observed histopathological patterns.

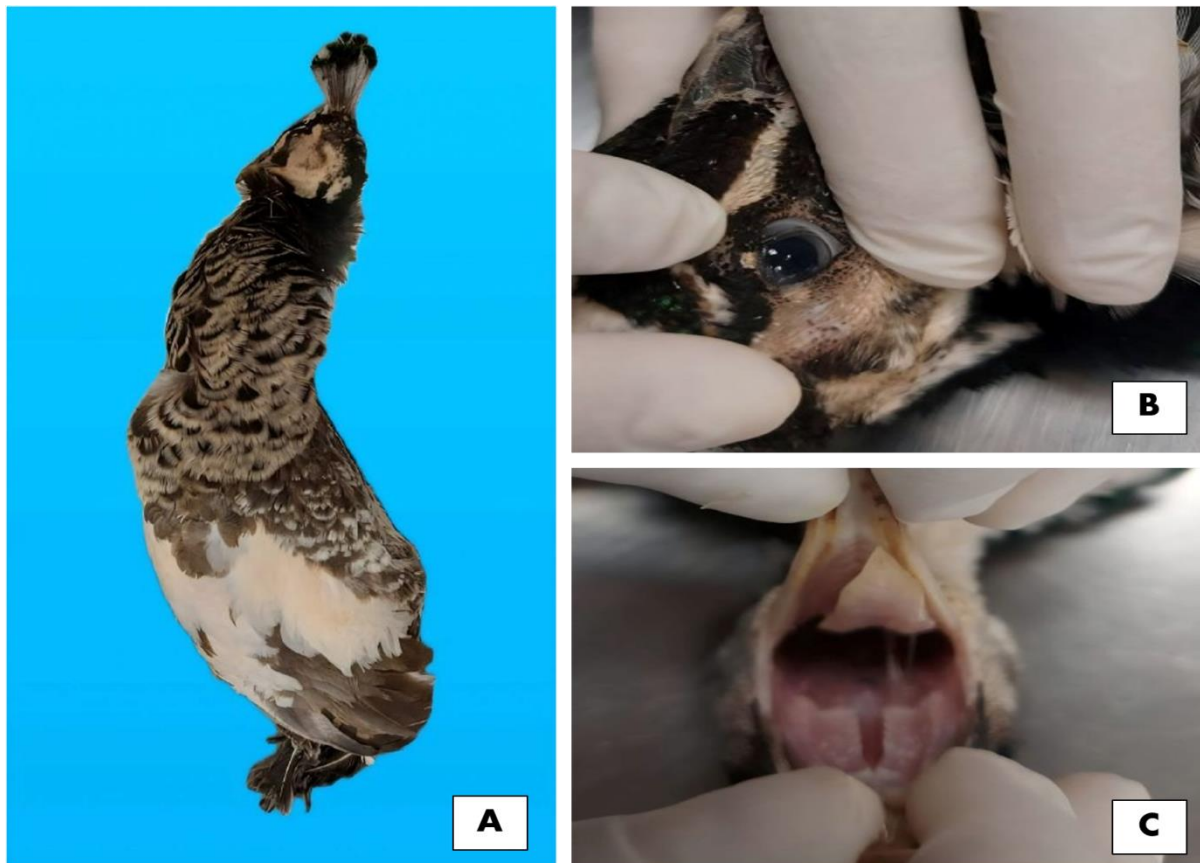Results and Discussion

Upon external examination of the carcass, a slight pallor of the oral and ocular mucous membranes was observed, along with moderate atrophy of the pectoral musculature and a prominent keel bone, characterizing a state of cachexia (Figure 1A–C). These findings are consistent with chronic diseases in birds, especially those affecting the digestive tract and liver, such as histomoniasis. In this condition, the destruction of the cecal mucosa and hepatic impairment lead to nutrient malabsorption and a negative energy balance. Such clinical and bodily alterations are frequently described in galliforms affected by the disease and reflect the systemic progression of the pathogen.

Upon opening the coelomic cavity, the air sacs appeared moderately opaque, thickened, and covered by a yellowish viscous material (Figure 2A), a finding consistent with airsacculitis. The lungs exhibited diffuse dark-red discoloration (Figure 2B), and upon sectioning, a small amount of serosanguinous frothy fluid was released, suggesting pulmonary congestion and edema. These macroscopic findings indicate significant respiratory impairment and are frequently observed in cases of avian aspergillosis, particularly in birds subjected to stress, immunosuppression, or concomitant systemic diseases.

The liver exhibited an irregular surface with multiple yellowish-white circular foci, which were friable and measured between 3 and 4 cm in diameter. Upon sectioning, these lesions extended into the parenchyma (Figure 2C), characterizing areas of multifocal coalescing necrosis. These lesions are considered typical of histomoniasis and are frequently described as "target-like" lesions, resulting from the protozoan's migration from the ceca to the liver via the portal circulation. The intensity and extent of these alterations indicate an advanced stage of infection and reinforce the high susceptibility of the Indian peacock to the disease compared to other galliform species.

Figure 1. External examination of the *Pavo cristatus* (Indian peacock) carcass. (A) Panoramic view of the carcass prepared for necropsy. (B) Evaluation of the ocular and (C) oral mucosa, showing slight pallor.



Upon evaluation of the ceca, marked thickening and mucosal irregularity were observed, with a large amount of yellowish-white friable material adhered to the wall, associated with extensive areas of loss of mucosal integrity (Figure 2D). Such alterations are characteristic of the fibrinonecrotic typhlitis observed in histomoniasis and represent the primary site of *Histomonas meleagridis* multiplication, constituting the initial point of infection. The observed lesion pattern is consistent with severe cases of the disease, involving mucosal destruction, an intense inflammatory response, and a predisposition to secondary bacterial infections.

Histopathological evaluation of the lungs revealed multifocal coalescing areas of necrosis associated with cellular debris (Figure 3A), accompanied by a moderate multifocal heterophilic inflammatory infiltrate. Numerous septate hyphae with parallel walls and acute-angle branching were identified, along with conidiophores consistent with *Aspergillus* spp. (Figure 3B), frequently filling the alveolar lumina. Special Grocott staining intensely highlighted these fungal structures within the pulmonary tissue (Figures 3C-D), allowing for the morphological diagnosis of necrotizing heterophilic pneumonia associated with aspergillosis. The presence of this fungal infection reinforces the role of systemic immunosuppression as a predisposing

factor, frequently described in birds affected by advanced stage histomoniasis.

In the liver, extensive multifocal coalescing areas of lytic necrosis were observed (Figure 4A), associated with a lymphohistioplasmacytic inflammatory infiltrate (Figure 4B), biliary duct hyperplasia, and mild periportal fibroplasia. Additionally, sinusoidal congestion, moderate multifocal hemorrhage, intracytoplasmic vacuolization in hepatocytes (consistent with mild steatosis), and accumulation of yellowish-brown pigment indicative of cholestasis were identified (Figure 4C). Amidst the necrotic areas, oval hypereosinophilic structures measuring between 2 and 5 μm in diameter were observed (Figure 4D), consistent with *Histomonas meleagridis* trophozoites.

Histopathological evaluation of the ceca revealed extensive areas of epithelial loss, replaced by multifocal coalescing necrosis associated with a large amount of cellular debris and fibrin, in addition to intralésional bacterial myriads. A multifocal coalescing lymphohistiocytic inflammatory infiltrate was observed involving the mucosa, submucosa, muscularis, and serosa, with numerous multinucleated giant cells containing round eosinophilic structures within their cytoplasm. Upon special PAS staining, these structures exhibited strong positivity, confirming them as *Histomonas meleagridis* trophozoites.

Figure 2. Internal organ evaluation of the *Pavo cristatus* (Indian peacock) carcass. (A) Moderately opaque air sacs with deposition of yellowish viscous material (Yellow arrow). (B) Lungs showing diffuse dark-red pulmonary lobes. (C) Liver with yellowish-white circular friable lesions, with slightly depressed centers and raised borders, measuring between 3 and 4 cm in diameter. (D) Cecum with markedly thickened and irregular mucosa, diffusely covered by a substantial amount of yellowish-white friable material.

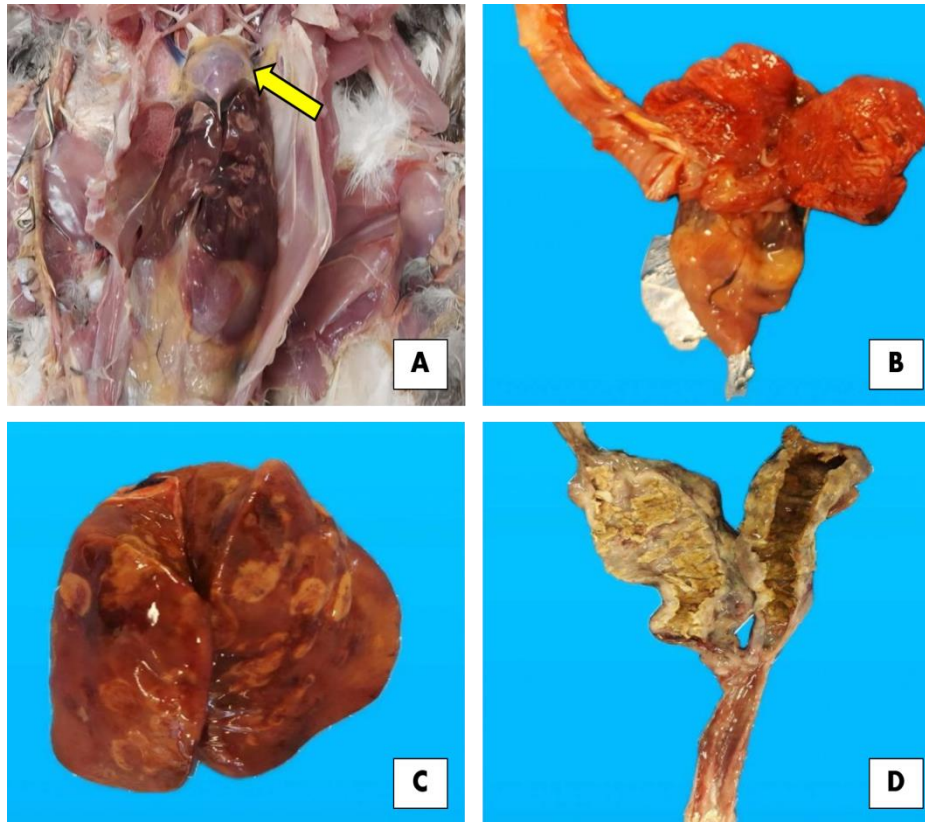
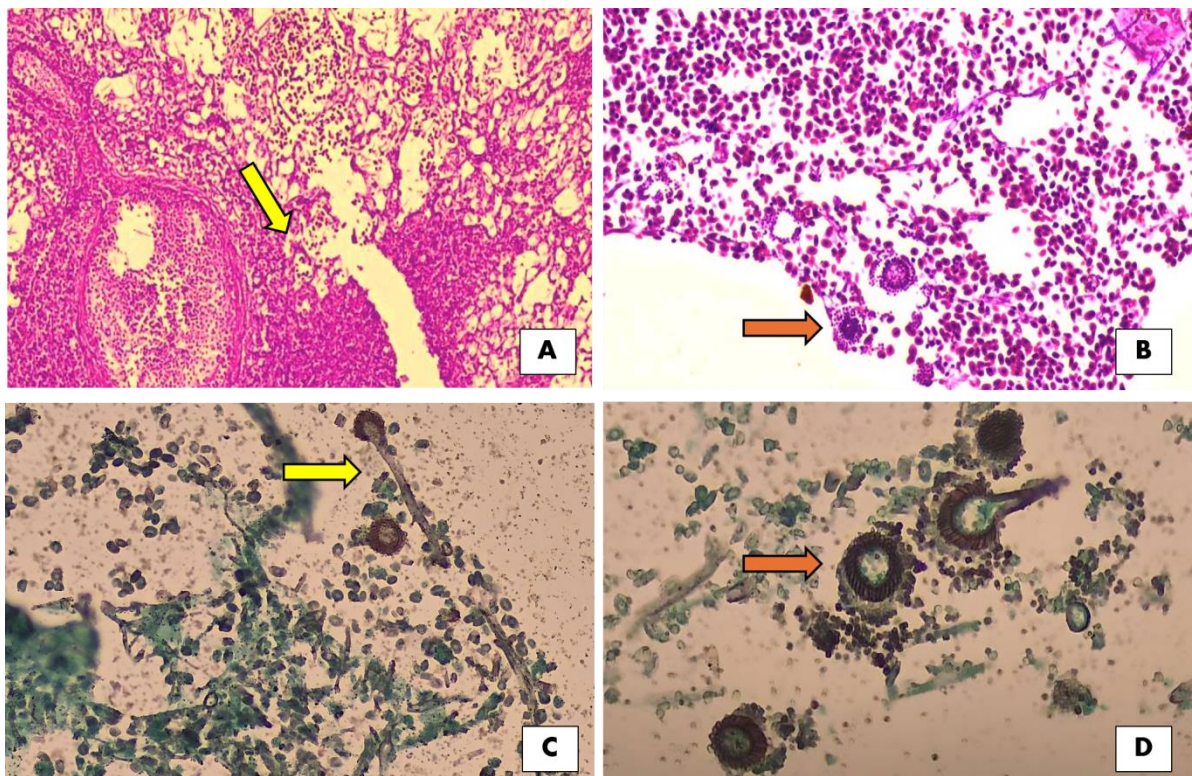


Figure 3. Histopathological evaluation of the lungs from the *Pavo cristatus* carcass. (A) Multifocal coalescing areas of necrosis and cellular debris (Yellow arrow). H&E, 10x. (B) Conidiophores (Orange arrow) consistent with *Aspergillus* spp. and erythrocytes filling the alveolar lumina. H&E, 40x. (C) Structures consistent with septate hyphae showing acute-angle branching (Yellow arrow). GMS, 40x. (D) GMS-positive structures composed of conidial heads, consistent with

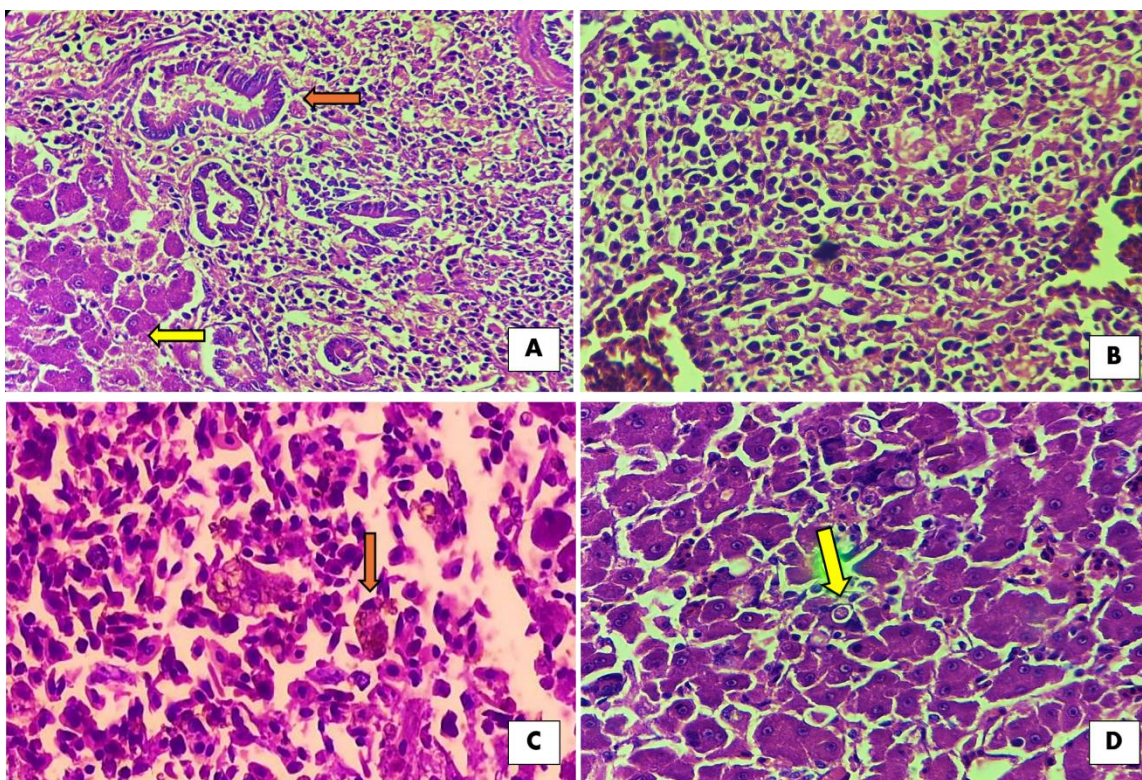


conidiophores and spores, characteristic of *Aspergillus* spp. GMS, 40x.

The integration of clinical, epidemiological, macroscopic, and histopathological findings allowed for the establishment of the following morphological diagnoses: necrotizing heterophilic pneumonia associated with *Aspergillus* spp.; multifocal coalescing periportal necrotizing granulomatous hepatitis with biliary hyperplasia; and marked

transmural granulomatous and fibrinonecrotic typhlitis. Consequently, it is concluded that the animal was affected by histomoniasis associated with aspergillosis, with the fungal infection interpreted as a secondary aggravating factor related to immunosuppression and the systemic impairment caused by the primary parasitosis.

Figure 4. Histopathological evaluation of the liver from the *Pavo cristatus* (Indian peacock) carcass. (A) Multifocal coalescing areas of parenchymal loss, replaced by lytic necrosis (Yellow arrow) and proliferated bile ducts, consistent with biliary hyperplasia (Orange arrow). H&E, 10x. (B) Predominantly lymphohistioplasmacytic inflammatory infiltrate. H&E, 40x. (C) Accumulation of yellowish-brown pigment within a hepatocyte, consistent with cholestasis (Orange arrow). H&E, 40x. (D) Oval eosinophilic structure measuring 4 μ m in diameter, consistent with a *Histomonas meleagridis* trophozoite. H&E, 40x.



Histomoniasis, also known as "blackhead disease," is a parasitic illness caused by the protozoan *Histomonas meleagridis*, which induces necrotizing lesions in the liver and ceca, potentially resulting in high mortality rates, particularly in turkeys. According to McDougald (2005), it is a classic disease in avian pathology, responsible for outbreaks with high mortality rates and significant economic losses in these animals. Recent studies confirm that *H. meleagridis* remains a pathogen of sanitary importance for both domestic and ornamental birds; despite advances in understanding its pathogenesis, widely available commercial vaccines do not yet exist (Beer et al., 2022).

Regarding epidemiological aspects, as reported by the owner, the peacock cohabited with

other birds (chickens and guinea fowl), a factor recognized as predisposing to the development of histomoniasis. Multi-species rearing with chickens is widely described as an epidemiological risk because they frequently act as asymptomatic reservoirs for *H. meleagridis* and *Heterakis gallinarum* eggs, contaminating the environment and facilitating infection in more sensitive species, such as peacocks and turkeys (Costa et al., 2018; Beer et al., 2022).

This is further supported by the fact that the *H. meleagridis* cycle begins with the ingestion of embryonated eggs of the nematode *Heterakis gallinarum*, which harbor the protozoan, by galliform hosts (Das et al., 2021). These eggs are shed in the feces of infected birds and can infect others through paratenic hosts, such as earthworms (Das et al.,

2021; Beer et al., 2022). Upon ingestion, the eggs hatch in the bird's cecum, releasing *H. meleagridis*, which invades the cecal mucosa, multiplies, and initiates local infection (Beer et al., 2022). Nevertheless, there is also evidence of direct transmission between birds through the ingestion of feces in high-population-density environments (Beer et al., 2022).

Clarke et al. (2017) also demonstrated that multi-species rearing increases the exposure of susceptible species, emphasizing that peacocks exhibit high sensitivity when kept in shared environments with carrier chickens. Thus, the mixed management observed in this case constitutes a significant predisposing factor involved in the epidemiological chain of the disease. In addition to the co-rearing of different avian species, Lunning et al. (2023) state that other factors, such as the lack of intestinal parasite control and contact with wild birds, favor the persistence of the pathogen in the environment—the latter being a possibility, as the bird in this case was raised in an open and exposed environment.

Despite this susceptibility, the disease varies among species; it is well known that turkeys (*Meleagris gallopavo*) are the most severely affected, while domestic chickens (*Gallus gallus domesticus*) tend to present subclinical or less lethal forms (McDougald, 2005). Other species, such as quail, partridges, and peacocks (*Pavo cristatus*), can also be affected, although natural occurrence in the latter is less frequent, highlighting the importance of describing cases such as the one in the present study (Clarke et al., 2017; Costa et al., 2018). Corroborating the aforementioned case, reports in peacocks demonstrate that the infection tends to progress with typical cecal and hepatic lesions, frequently resulting in a fatal outcome (Costa et al., 2018).

Phenotypic and genetic variations exist among *H. meleagridis* isolates, which may explain differences in virulence between strains (Wei et al., 2020). Furthermore, several authors have demonstrated that the protozoan is anaerobic and undergoes primary replication in the ceca, with subsequent migration to the liver, where it produces the typical necrotic lesions of the disease (Hauck et al., 2006; McDougald, 2005; Grabensteiner et al., 2006). These findings reinforce the observations in the current case, in which the ceca and liver were the primary organs affected; such lesions are recognized as "anatomopathological markers" of histomoniasis (McDougald, 2005; Clarke et al., 2017).

The clinical alterations and deaths restricted to the peacocks on the property may be directly associated with the more ineffective and subsequently exacerbated immune response of this species. The extent of the cecal and hepatic lesions observed in the described bird can be understood through the variability of the immune response between species (chickens vs. peacocks). Chickens early activate cytokines such as IL-1 β and IL-6 in the

ceca, which limits the parasite's migration to the liver. In contrast, peacocks fail in this initial response, allowing the parasite to propagate and culminating in an exacerbated response in the liver, characterized by elevated levels of IFN- γ , IL-4, IL-13 and IL-10 (Powell et al., 2009). Furthermore, the systemic response in peacocks is more intense. Investigations of the T-lymphocyte profile in vaccinated/infected peacocks revealed a significant increase in producing T-cells IFN- γ (CD4⁺, CD8 α ⁺, CD3⁺CD4⁻CD8 α ⁻) in the spleen and liver (Lagler et al., 2020).

Although the bird presented lesions in the liver and ceca, organs classically affected by the pathogen, other tissues may be involved in severe or systemic cases. Involvement of digestive tract regions such as the small intestine, colon, and rectum has been described, especially in intense infections, featuring inflammatory infiltration and focal necrosis (Beer et al., 2022). Extraintestinal lesions have also been documented in reproductive system organs, such as the ovary and oviduct, characterized by granulomatous inflammation and multifocal necrosis (Michelazzo, 2017). Additionally, hematogenous dissemination may lead the agent to cause alterations in the lungs, spleen, kidneys, pancreas, heart, and bursa of Fabricius, although involvement of these organs is less frequent and generally associated with severe infections or immunosuppression (Clarke et al., 2017).

Among the clinical signs reported by the bird's owner, such as apathy, drooping wings, and ruffled feathers, these are considered some of the most characteristic findings of the disease (McDougald, 2005). In severe cases, extreme lethargy and cyanosis of the head and comb—which justifies the popular name "blackhead disease", as well as isolation from the flock and a hunched posture, may be observed (Clarke et al., 2017). The clinical progression is typically rapid in susceptible species, often resulting in sudden death due to hepatic and cecal impairment (Beer et al., 2022). The severity of clinical manifestations may be exacerbated by variations in the virulence of the isolate and secondary bacterial or fungal infections (Wei et al., 2020), factors that, in the case of the bird reported here, were confirmed by histopathological examination, which revealed bacterial myriads in the cecal tissue and fungal hyphae in the pulmonary alveoli.

Thus, the anatomopathological alterations allowed for the diagnosis of histomoniasis associated with aspergillosis in a peacock. The diagnosis was established primarily through histological evaluation, which revealed intracellular trophozoites within multinucleated giant cells and histiocytes of the cecal mucosa. These findings were consistent with previous descriptions reported in peacocks in the literature (Costa et al., 2018; Souza et al., 2021). Furthermore, the visualization of hyphae and conidiophores within the parabronchial lumina enabled the diagnosis of pulmonary

aspergillosis, an agent with a morphology previously described by Aziz et al. (2016).

The gross lesions observed during necropsy developed as a result of parasitic infiltration into the mucosal, submucosal, and muscular layers of the ceca, triggering intense inflammation, necrosis, wall thickening, and the formation of ulcers within the lumen. Subsequently, *H. meleagridis* migrates to the liver via the portal vein, where it induces well-demarcated necrotic foci, frequently described as "target-like" lesions, similar to those observed and described in the present study (Lund & Chute, 1972; Beer et al., 2022). This migration and hepatic colonization result in hepatocyte dysfunction, impairment of metabolic function, and necrotizing hepatitis, which can lead to liver failure in susceptible birds (Beer et al., 2022). Consequently, there is a reduction in nutrient absorption, intensifying the clinical condition (Das et al., 2021)—a mechanism that explains the progressive weight loss reported by the owner.

The observed secondary fungal infection is justified, according to Clark & Kimminau (2017), by the profound immune dysregulation caused by histomoniasis, which includes destruction of the intestinal mucosal barrier, reduced phagocytic activity of macrophages and heterophils, and impairment of cellular and inflammatory immune responses. These mechanisms, also extensively described by McDougald (2005), explain how tissue damage and protozoan-induced immunosuppression favor the establishment of secondary infections, including fungal agents that would normally be controlled in immunocompetent birds.

Consequently, during histopathological examination, the use of the Periodic Acid-Schiff (PAS) special stain proved fundamental in highlighting the protozoan within the lesions; as recommended by Hess et al. (2015), this stain enhances the trophozoites' cytoplasm and aids in differentiating them from cellular debris or bacterial structures. In parallel, Hussein et al. (2015) state that molecular methods, such as Polymerase Chain Reaction (PCR)—both conventional and real-time—constitute highly sensitive and specific tools, being widely employed in diagnostic laboratories for etiological confirmation, detection of low parasitic loads, and differentiation between isolates.

Although not applied to the context of the present case, the use of serological tests, such as ELISA, has also been evaluated for flock screening, especially in commercial rearing where population monitoring is fundamental. However, this method presents significant limitations, primarily due to the difficulty in distinguishing between active infection and previous exposure to the pathogen, which reduces its utility for individual diagnosis and restricts its application mainly to epidemiological studies and sanitary surveillance strategies (Majidi et al., 2025).

The protocol adopted by the owner, involving the use of levamisole and dexamethasone, is only partially in agreement with literature

recommendations for histomoniasis. The use of levamisole, although lacking direct action against *H. meleagridis*, may be justified by the attempt to control *H. gallinarum*, which is epidemiologically coherent and aligns with the preventive practices described by McDougald (2005) and Jones et al. (2020). However, once the infection is established, this drug does not interfere with the disease's progression, differing from experimentally investigated compounds such as nitarosone, paromomycin, and nitroimidazoles (Bleyen et al., 2009; Hess et al., 2015).

The subsequent administration of dexamethasone, while capable of reducing inflammatory signs, does not act upon the etiological agent and may favor secondary infections due to its immunosuppressive effect. This contrasts with current recommendations that prioritize supportive measures and management to avoid complications and opportunistic agents (Clarke et al., 2017). Thus, it is observed that, although some decisions reflected a concern with vector control, the treatment employed did not align with the effective conducts described in the literature for histomoniasis.

The initially recommended therapeutic approach includes the use of drugs from the nitroimidazole and benzimidazole classes (Hu & McDougald, 2004), which are historically effective against *H. meleagridis*, despite their regulatory restrictions. Consequently, the treatment of histomoniasis is challenging, as the use of most of these recommended compounds has been banned in food-producing birds due to concerns regarding residues and food safety (Beer et al., 2022). Additionally, experimental studies indicate that compounds such as nitarosone (an arsenical) and paromomycin exhibit therapeutic or prophylactic effects, reducing the severity of lesions and mortality in turkeys and chickens (Bleyen et al., 2009; Hess et al., 2015).

Although this case focused on the clinical-pathological aspects of histomoniasis, it is worth emphasizing that prevention and control strategies are based on management measures, such as avoiding the co-rearing of chickens and peacocks, preventing access to earthworms, performing regular deworming, and avoiding the reuse of contaminated areas (Jones et al., 2020; McDougald, 2005). For aspergillosis, the focus lies on preventive environmental management practices, such as maintaining a clean and dry environment and ensuring proper ventilation with dust and humidity control (Saad, 2025; Agbato et al., 2025). Although effective antifungals exist, their use for treatment in production birds is limited by a lack of registration and pharmacokinetic challenges, reinforcing that management and prevention remain the main pillars for controlling both diseases (Orosz, 2003; Alhassani et al., 2025).

Conclusion

The present case highlights the relevance of histomoniasis as a significant disease in ornamental

birds, especially under conditions that favor immunosuppression and secondary infections, such as aspergillosis. It underscores the importance of a comprehensive diagnostic approach involving complete clinical-pathological evaluation. The peacock cohabited with chickens and guinea fowl—a condition widely recognized as predisposing, as these birds act as asymptomatic reservoirs for *Histomonas meleagridis* and *Heterakisgallinarum* eggs, contaminating the environment and exposing more sensitive species like peacocks and turkeys. Additionally, the lack of parasite control and potential contact with wild birds may favor the persistence of the pathogen in the environment, factors that were also considered in this case.

The epidemiological cycle reinforces this risk, as it begins with the ingestion of embryonated *H. gallinarum* eggs containing *H. meleagridis*, which are shed in feces and capable of infecting hosts either directly or through paratenic hosts, such as earthworms. After hatching in the ceca, the protozoan invades the mucosa, multiplies, and triggers characteristic lesions; direct transmission is also possible in densely populated environments. Thus, the mixed-species management observed in this case represents a central link in the epidemiological chain of the disease, reinforcing the need for rigorous biosecurity measures. Early recognition, coupled with the control of predisposing factors, remains the primary strategy to prevent outbreaks and minimize sanitary losses in ornamental bird rearing.

References

- ABDELHAMID, M. K. et al. Co-infection of chicken layers with *Histomonas meleagridis* and avian pathogenic *Escherichia coli* is associated with dysbiosis, cecal colonization and translocation of the bacteria from the gut lumen. **Frontiers in Microbiology**, v. 11, p. 586437, 2020. DOI: 10.3389/fmicb.2020.586437.
- ABDELHAMID, M. K. et al. Disparity in the gut wall penetration by *Escherichia coli* during co-infection with *Histomonas meleagridis* in chickens and turkeys. **Veterinary Research**, v. 54, n. 1, 2023.
- ABDUL-AZIZ, T.; BARNES, H. J.; FLETCHER, O. J.; SHIVAPRASAD, H. L.; SWAYNE, D. E. **Avian Histopathology**. 4. ed. Jacksonville, FL: American Association of Avian Pathologists, 2016. 654 p.
- AGBATO, O. A. et al. Aspergillosis in Poultry: Impact and Flock Health Management – A Case Study. **Moor Journal of Agricultural Research**, v. 25, n. 1, p. 75–80, 2025.
- ALHASSANI, A. N. et al. A review on Aspergillosis in turkey: As a main fungal disease in poultry. **Veterinary Medicine and Science**, v. 11, n. 6, e70605, 2025.
- ALI, S.; RIPLEY, S. D. **Handbook of the Birds of India and Pakistan**. Oxford University Press, 1981.
- BECKMANN, J. F. et al. *Heterakisgallinarum* and *Histomonas meleagridis* DNA persists in chicken houses years after depopulation. **Veterinary Parasitology**, v. 298, p. 109536, 2021.
- BEER, L. C. et al. Histomonosis in poultry: a comprehensive review. **Frontiers in Veterinary Science**, v.9, 880738, 2022.
- BLEYEN, N. G. et al. Non-curative, but prophylactic effects of paromomycin in *Histomonas meleagridis*-infected turkeys and its effect on performance in non-infected turkeys. **Veterinary Parasitology**, v. 165, n. 3–4, p. 248–255, 2009.
- CLARK, S.; KIMMINAU, E. Critical review: future control of blackhead disease (*Histomoniasis*) in poultry. **Poultry Science**, v. 96, n. 10, p. 3671–3681, 2017.
- CLARKE, L. L. et al. Pathologic and molecular characterization of histomoniasis in peafowl (*Pavo cristatus*). **Journal of Veterinary Diagnostic Investigation**, v. 29, n. 5, p. 1–7, 2017.
- COOKSON, K. C.; SHIVAPRASAD, H. L. Infection with *Mycoplasma gallisepticum* in chukar partridges, pheasants and peafowl. **Avian Diseases**, v. 38, n. 4, p. 914–921, 1994.
- COSTA, R. A.; PEREIRA, A. P. M.; SILVEIRA, C. S.; ANJOS, B. L. Infecção natural por *Histomonas meleagridis* em pavões-indianos (*Pavo cristatus*). **Acta Scientiae Veterinariae**, v. 46, p. 5, 2018.
- DAS, G. et al. Excretion of *Histomonas meleagridis* following experimental co-infection of distinct chicken lines with *Heterakisgallinarum* and *Ascaridia galli*. **Parasites & Vectors**, v. 14, n. 1, 2021.
- DELACOUR, J. **The Pheasants of the World**. 2. ed. Oxford University Press, 1977.
- GRABENSTEINER, E. et al. Broad dissemination of *Histomonas meleagridis* determined by detection of nucleic acid in different organs after experimental infection of turkeys and SPF chickens. **Parasitology International**, v. 55, n. 4, p. 317–322, 2006.
- HAUCK, R.; LIISCHOW, D.; HAFEZ, H. M. Detection of *Histomonas meleagridis* DNA in different organs after natural and experimental infections of meat turkeys. **Avian Diseases**, v. 50, n. 1, p. 35–38, 2006.
- HESS, M. et al. *Histomonas meleagridis* – new insights into an old pathogen. **Veterinary Parasitology**, v. 208, n. 1–2, p. 67–76, 2015.

- HU, J.; McDOUGALD, L. R. The efficacy of some drugs with known antiprotozoal activity against *Histomonas meleagridis* in chickens. **Veterinary Parasitology**, v. 121, n. 3–4, p. 233–238, 2004.
- HUSSAIN, K. et al. Detection and quantification of *Histomonas meleagridis* by real-time PCR targeting single-copy genes. **Veterinary Parasitology**, v. 212, n. 3–4, p. 382–388, 2015.
- IBAMA. **Instrução Normativa nº 10, de 20 de setembro de 2013**. Brasília: Instituto Brasileiro do Meio Ambiente e dos Recursos Naturais Renováveis, 2013.
- JOHNSGARD, P. A. **The Pheasants of the World: Biology and Natural History**. 2. ed. Washington: Smithsonian Institution Press, 1999.
- JONES, R. E. et al. Histomoniasis outbreaks in commercial turkeys in the southeastern United States: proximity of broiler breeder farms as a potential risk factor. **Journal of Applied Poultry Research**, v. 29, n. 2, p. 496–501, 2020.
- KEAR, J. **Ducks, Geese and Swans**. Oxford University Press, 2005.
- LAGLER, J. et al. Comparative investigation of IFN- γ -producing T cells in chickens and turkeys following vaccination and infection with *Histomonas meleagridis*. **Veterinary Research**, 2020.
- LUND, E.E.; CHUTE, A.M. *Heterakis* and *Histomonas* infections in young peafowl, compared to such infections in pheasants, chickens, and turkeys. **J. Wildl Dis.**, v.8, n.4 ,p.352-358, 1972.
- LÜNING, J. et al. Investigations of histomonosis-favouring conditions: a hypotheses-generating case-series study. **Animals**, v. 13, n. 5, 2023.
- MAJIDI, A.; BARARI, A.; TOLOOE, A. Emerging histomoniasis in poultry farms: a narrative review. **Journal of Poultry Sciences and Avian Diseases**, v. 3, n. 4, p. 82–93, 2025.
- McDOUGALD, L. R. Blackhead disease (histomoniasis) in poultry: a critical review. **AvianDiseases**, v. 49, n. 4, p. 462–476, 2005.
- MICHELAZZO, M. et al. Histomoníase sistêmica em um pavão-índio leucístico (*Pavo cristatus*) do sul do Brasil. **Pesquisa Veterinária Brasileira**, v. 37, n. 3, p. 325–329, 2017.
- OROSZ, S. E. Antifungal drug therapy in avian species. **Veterinary Clinics of North America: Exotic Animal Practice**, v. 6, n. 2, p. 337–350, 2003.
- POWELL, F. L. et al. The turkey, compared to the chicken, fails to mount an effective early immune response to *Histomonas meleagridis* in the gut. **Parasite Immunology**, v. 31, n. 6, p. 312–327, 2009.
- SAAD, M. M. Review about aspergillosis in poultry. **Egyptian Journal of Veterinary Sciences**, 2025.
- SOUSA, A. C. F. C. et al. Histomoníase em pavão (*Pavo cristatus*) no semiárido potiguar. **Acta Scientiae Veterinariae**, v. 49, 2021.
- WEI, Z. et al. *Histomonas meleagridis* isolates compared by virulence and gene expression. **Veterinary Parasitology**, v. 286, p. 109233, 2020.